

VULVAR SQUAMOUS INTRAEPITHELIAL LESIONS

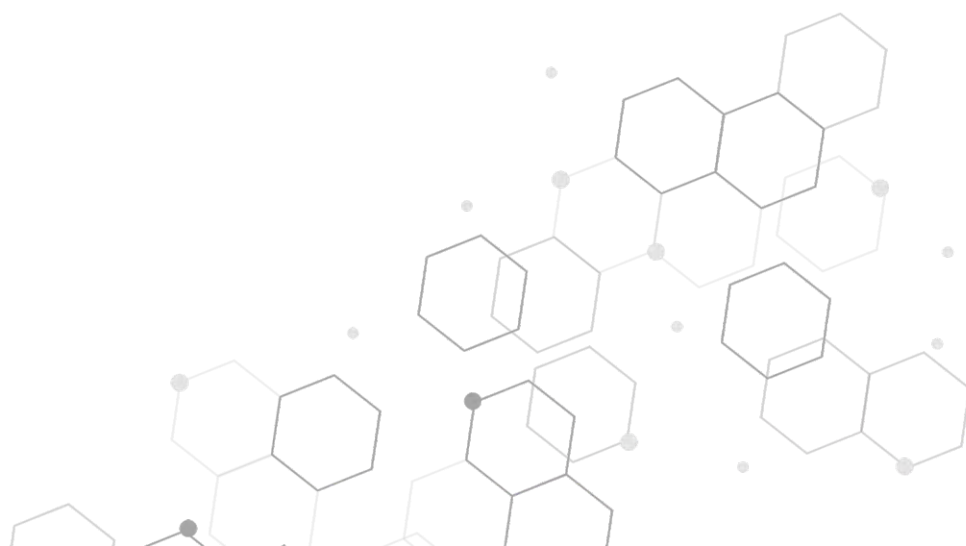(Previously called vulvar
intraepithelial neoplasia
or VIN)



What are vulvar squamous intraepithelial lesions?

Low grade squamous intraepithelial lesions (LSIL), high grade squamous intraepithelial lesions (HSIL) and differentiated vulvar intraepithelial neoplasia (dVIN) are the names given to the presence of abnormal squamous cells on the vulvar skin. These areas can occur as one patch or they may affect several areas of skin at the same time.

These lesions are not cancer. LSIL are also known as warts. They do not become cancer and don't need treatment unless they are causing symptoms. HSIL and dVIN may develop into cancer if not treated.






Who gets LSIL, HSIL and dVIN of the vulva?

These lesions can occur in women of all ages. LSIL and HSIL are commonly seen in young women, and the dVIN type is typically seen in older women.

What causes LSIL, HSIL and dVIN of the vulva?

The strains of human papilloma virus (HPV) which cause most genital warts are usually related to LSIL of the vulva. The strains of HPV that can cause genital cancers can cause HSIL of the vulva. The low grade and high grade squamous intraepithelial lesions are more common in smokers. They are also more common in women who are immunosuppressed, either from disorders affecting their immune system or from medication used to treat other types of disease. dVIN is often seen in women with other chronic vulvar skin conditions such as lichen sclerosus and lichen planus.



What are the symptoms of HSIL and dVIN?

Some women with HSIL experience itching or burning, but many women have no symptoms at all. dVIN usually occurs in women with a long-lasting history of itching, soreness and dryness.

What do the HSIL and dVIN lesions look like?

The abnormal area of skin may be noted at a routine examination or may be found by the patient who can feel it or see the abnormal area, they don't have a specific pattern. Sometimes HSIL presents as one patch or there may be several patches. Lesions can be white, grey, brown or red. They can be rough or smooth, flat or raised. They can occur anywhere on the vulva or around the anal area, and may

be confused with genital warts.

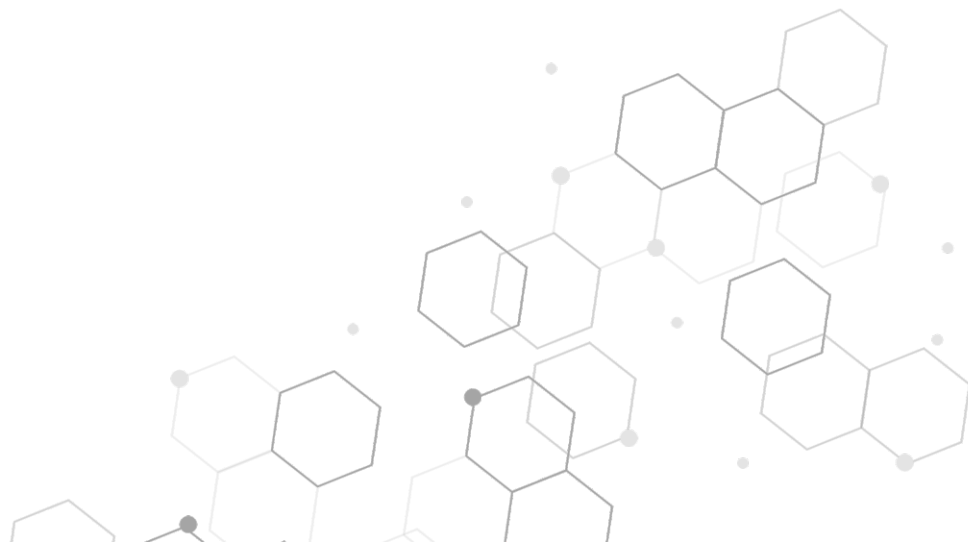The changes of dVIN are less specific than HSIL. dVIN is suspected when treatment-resistant, pink or white areas are seen on examination of the vulva. The dVIN lesions are sometimes difficult to tell apart from lichen sclerosus or lichen planus.

How is it diagnosed?

Your provider will ask questions relevant to the problem and will examine the area. A simple procedure called a skin biopsy will confirm the diagnosis. A small piece of skin from the affected area will be removed under local anaesthetic and then analyzed. If the diagnosis is confirmed, you may need further examination including a vulvoscopy which involves a bright light and magnification to look at the skin.

What happens to LSIL of the vulva?

Many areas of LSIL will resolve without treatment. If desired, a variety of treatments for genital warts can be used including medications on the skin or surgery.



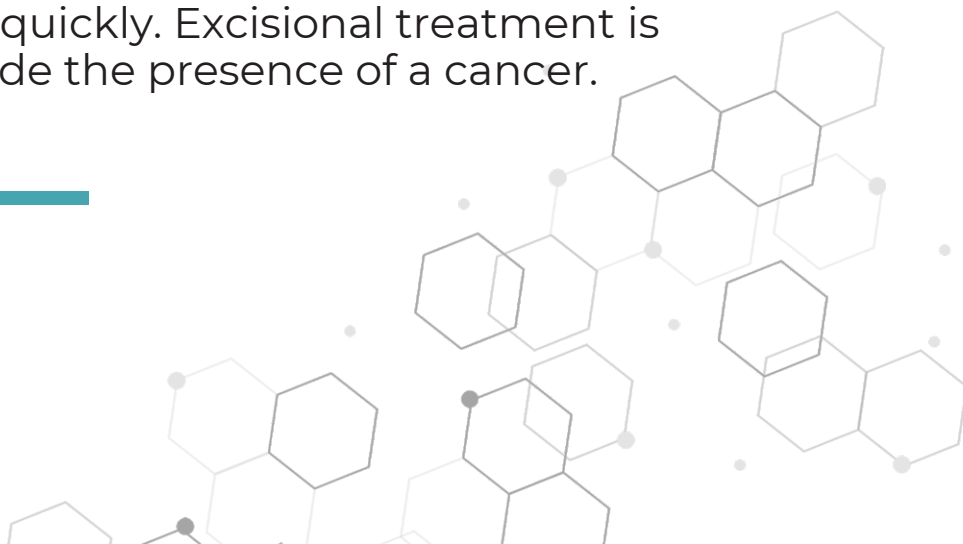What happens to HSIL of the vulva?

The majority of HSIL cases require treatment because some areas may develop into an invasive vulvar cancer. If the area is small, then it can be removed surgically or sometimes it can be lasered. If there are multiple lesions or larger areas affected, then imiquimod can be used to treat HSIL.

Other less commonly used treatments include 5 fluorouracil, cidofovir cream, or, photodynamic therapy. Your health care provider will discuss the best treatment for your case with you. It is important to note that these lesions do not affect child-bearing.

What happens to dVIN of the vulva?

As dVIN has a higher chance of becoming cancer than HSIL, it is often treated quickly. Excisional treatment is recommended to exclude the presence of a cancer.



What about follow-up?

Regular follow-up is essential to detect any recurrence. Unfortunately, recurrences are common. It is also important that you have regular cervical/vaginal screening as it is common to have cervical or vaginal lesions in addition to vulvar lesions.

What can I do to prevent these lesions?

The HPV vaccine has been shown to decrease the chance of developing vulvar LSIL/genital warts and vulvar HSIL.

The vaccine won't get rid of an HPV strain you already have but most people don't have all of the strains the vaccine covers and thus the vaccine is still recommended.

Effective treatment of inflammatory skin conditions such as lichen sclerosus and lichen planus may help to reduce the risk of developing dVIN.